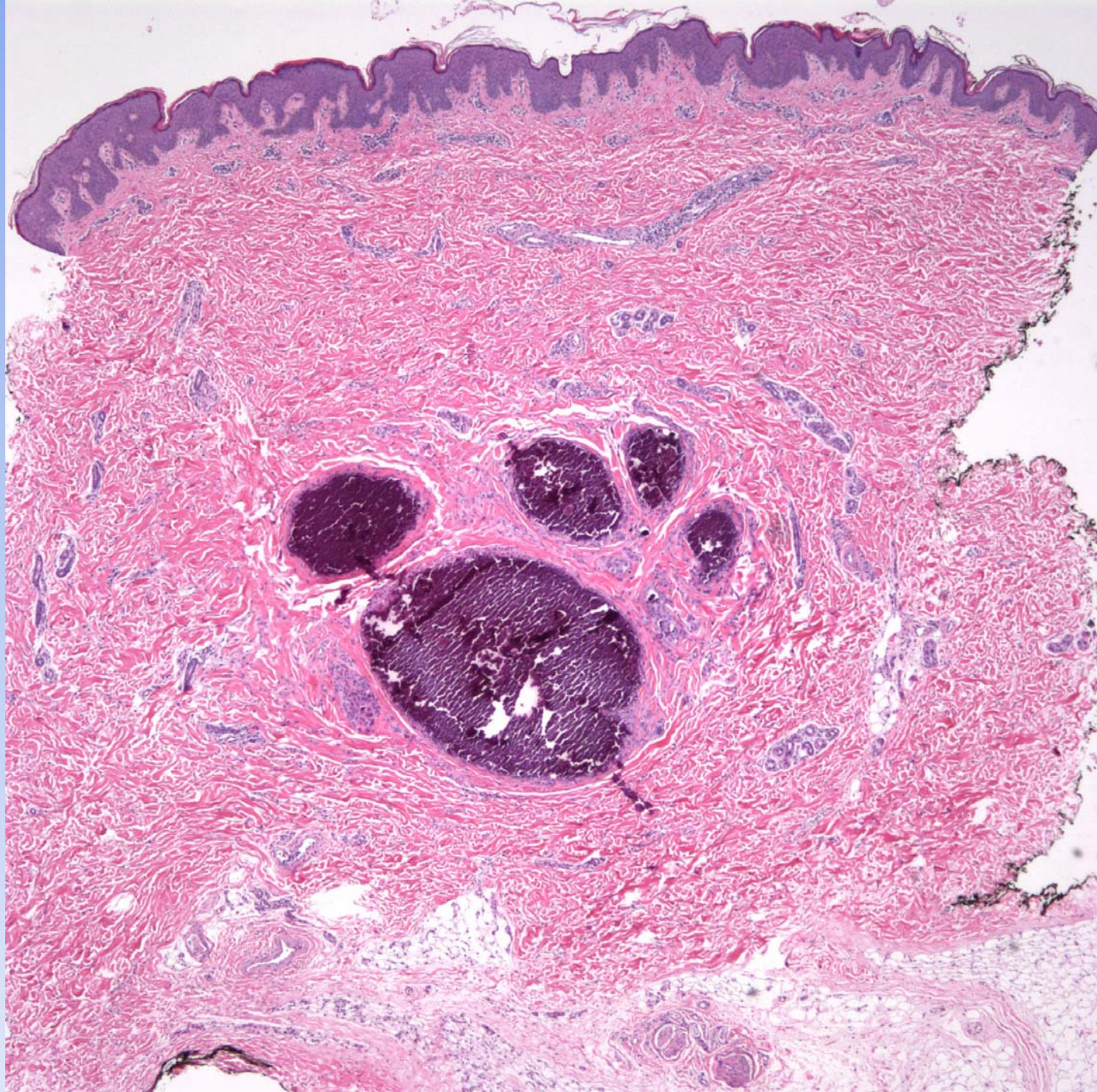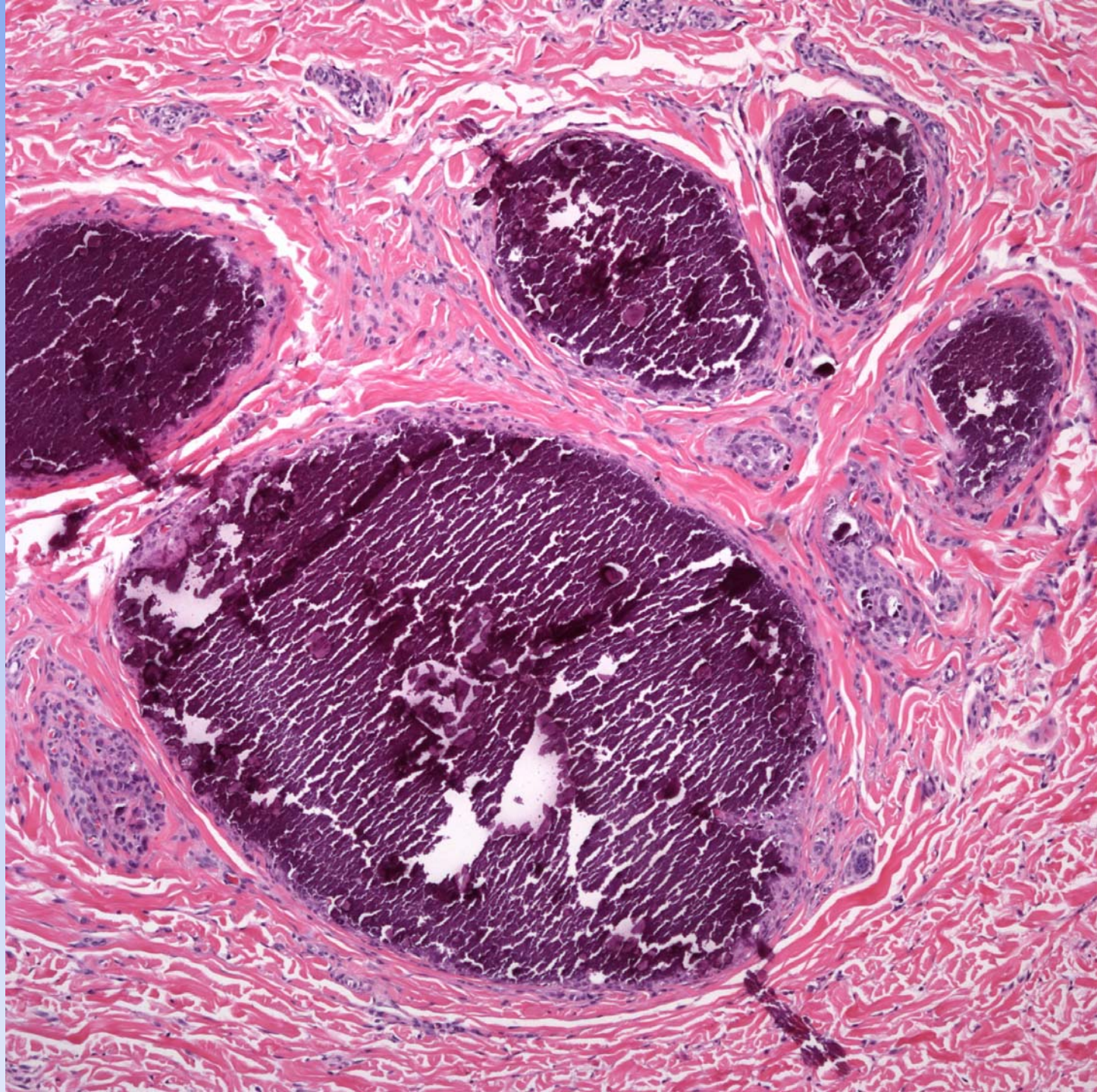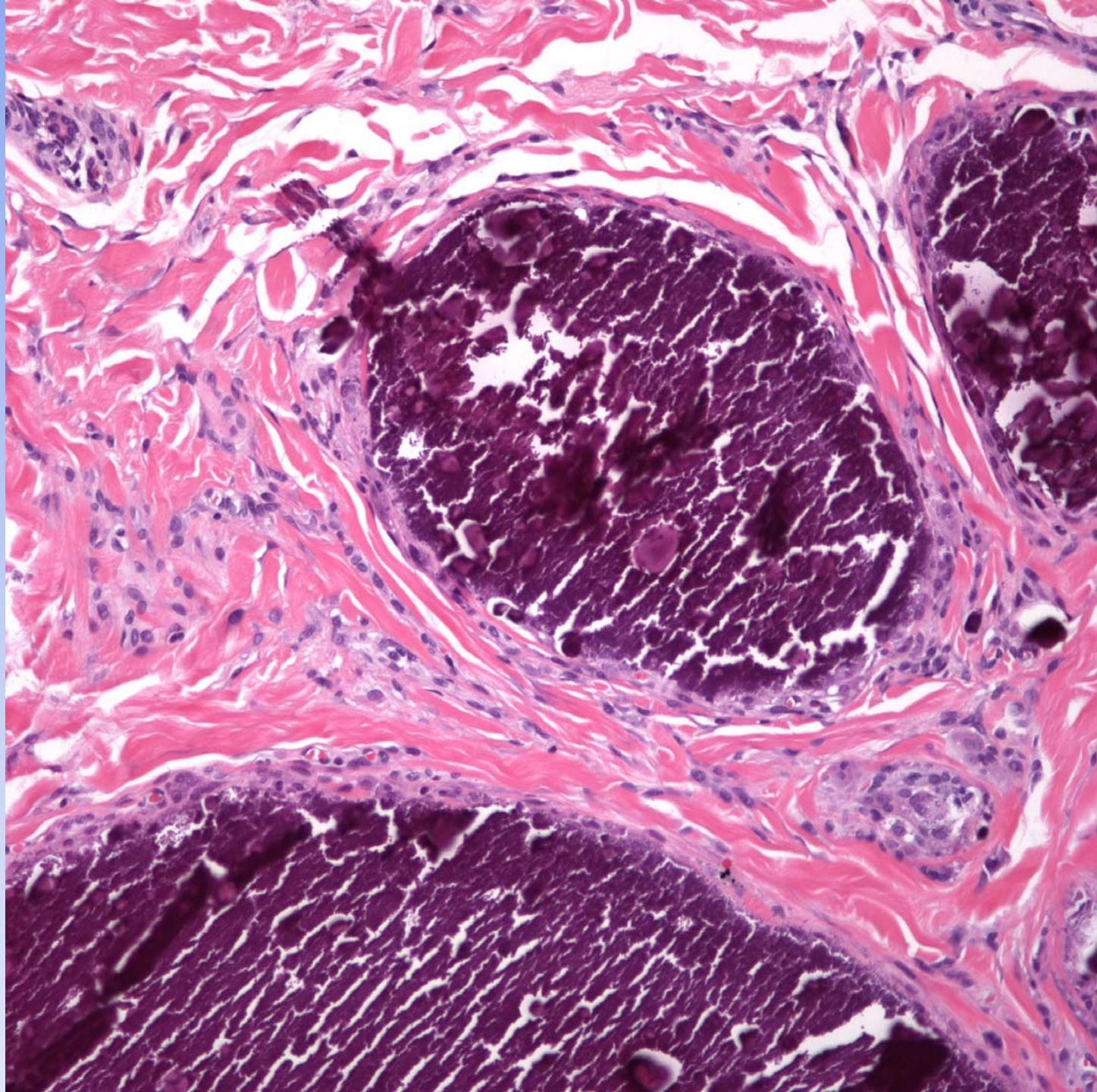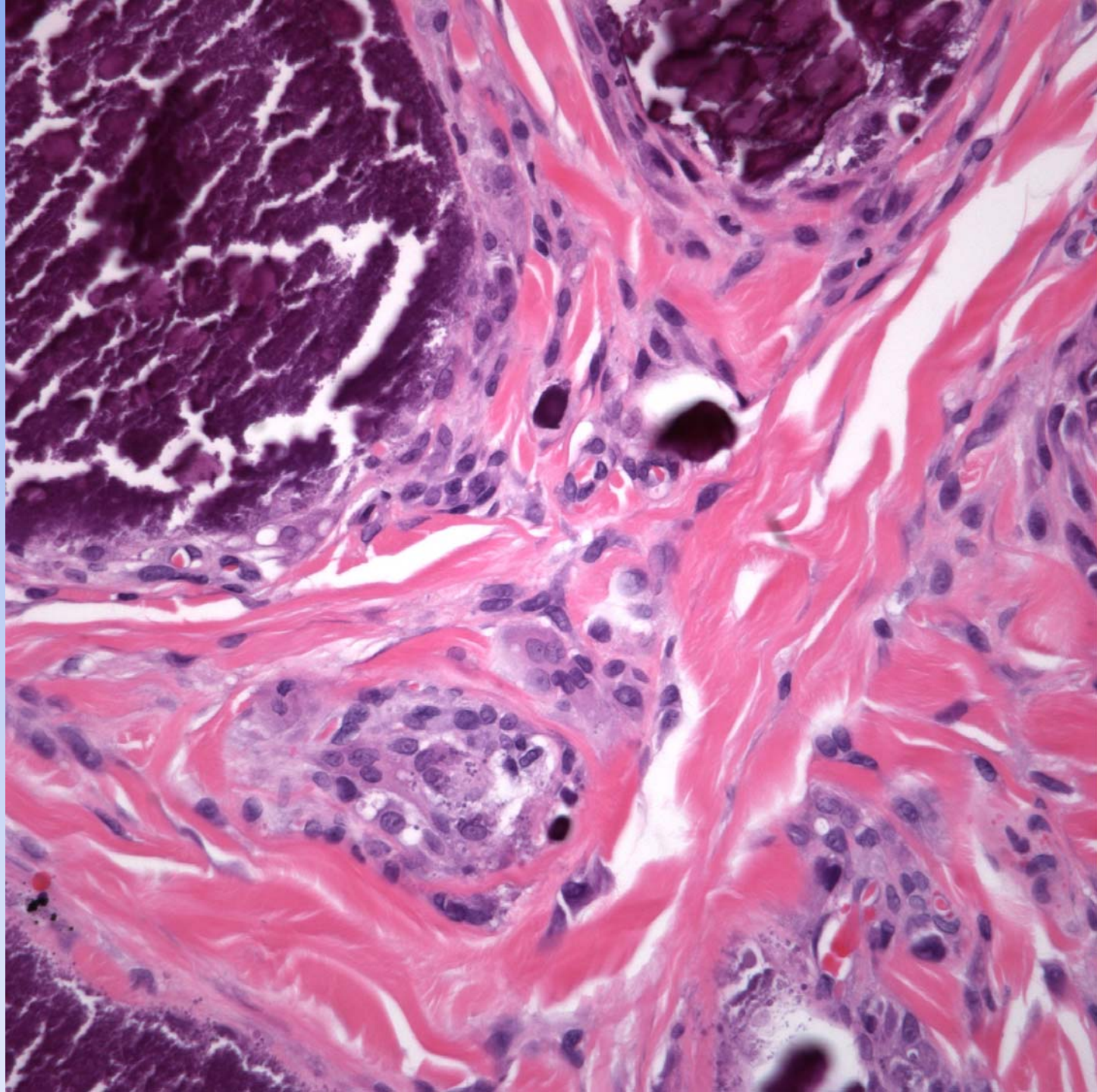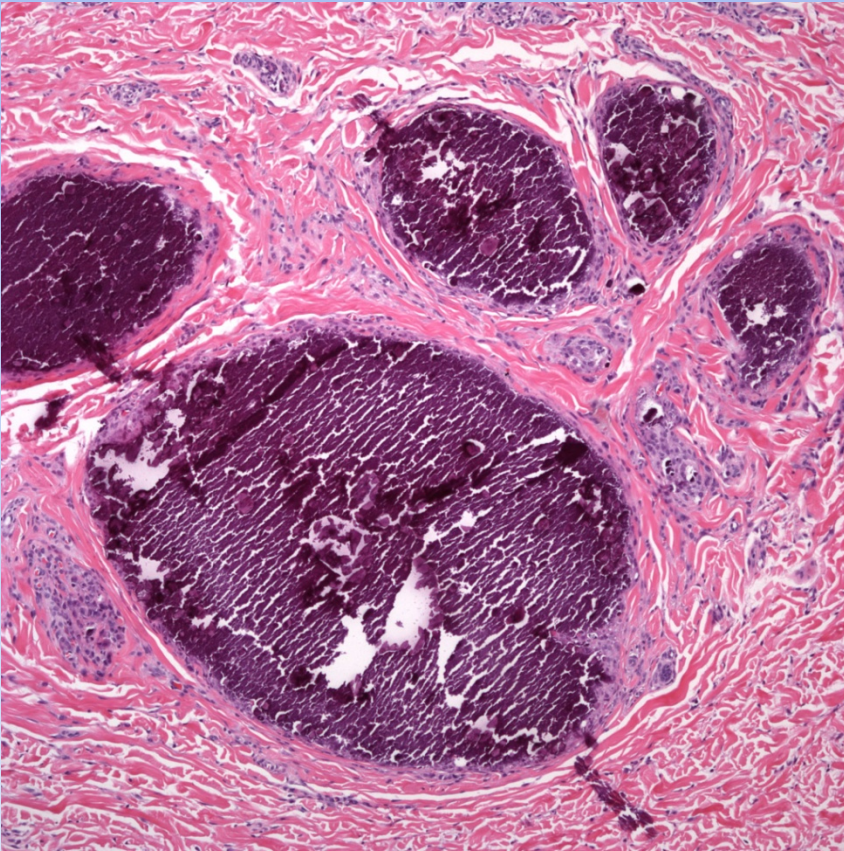


Tumoral Calcinosis

Pearls



- Circumscribed nodules of calcified amorphous debris
- No epithelial lining
- May be surrounded by foreign body type giant cells